From www.bloodjournal.org by on August 20, 2009. For personal use only.

blood

2009 114: 1469-1476
Prepublished online Jun 25, 2009;
doi:10.1182/blood-2009-02-179739

How I treat mantle cell lymphoma

Michele Ghielmini and Emanuele Zucca

Updated information and services can be found at:
http://bloodjournal.hematologylibrary.org/cgi/content/full/114/8/1469

Articles on similar topics may be found in the following *Blood* collections:
How I Treat (29 articles)
Free Research Articles (714 articles)
Lymphoid Neoplasia (217 articles)

Information about reproducing this article in parts or in its entirety may be found online at:
http://bloodjournal.hematologylibrary.org/misc/rights.dtl#repub_requests

Information about ordering reprints may be found online at:
http://bloodjournal.hematologylibrary.org/misc/rights.dtl#reprints

Information about subscriptions and ASH membership may be found online at:
http://bloodjournal.hematologylibrary.org/subscriptions/index.dtl

Blood (print ISSN 0006-4971, online ISSN 1528-0020), is published semimonthly by the American Society of Hematology, 1900 M St, NW, Suite 200, Washington DC 20036.
Copyright 2007 by The American Society of Hematology; all rights reserved.

From www.bloodjournal.org by on August 20, 2009. For personal use only.

How I treat mantle cell lymphoma

Michele Ghielmini[1] and Emanuele Zucca[1]

[1]Oncology Institute of Southern Switzerland, Bellinzona, Switzerland

Mantle cell lymphoma is included in the World Health Organization classification as distinct lymphoma subtype characterized by the t(11;14)(q13;q32) translocation, which results in overexpression of Cyclin D1. The clinical presentation often includes extranodal involvement, particularly of the bone marrow and gut. The prognosis of patients with mantle cell lymphoma (median overall survival, 3-5 years) is poorest among B-cell lymphoma patients, even though a prospectively difficult to identify subgroup can survive for years with little or no treatment. Conventional chemotherapy is not curative but obtains frequent remissions (60%-90%) which are usually shorter (1-2 years) compared with other lymphoma entities. Very intensive regimens, including autologous and allogeneic stem cell transplantation, seem required to improve the outcome, but with the median age of diagnosis being 60 years or more, such approaches are feasible only in a limited proportion of patients. The possibility of treating patients based on prognostic factors needs to be investigated prospectively. (Blood. 2009;114: 1469-1476)

Introduction

The lymphoma nowadays included in the WHO classification with the name "mantle cell lymphoma" (MCL)[1] was first described by K. Lennert more than 30 years ago, and subsequently defined "centrocytic lymphoma" in the Kiel classification,[2] but MCL was finally accepted as a separate entity only in the early 1990s, when it became evident that the t(11,14)(q13;q32) translocation was consistently present.[3,4]

Histologic diagnosis

The term MCL derives from the growth pattern of this lymphoma in its early stages, with neoplastic cells surrounding residual reactive germinal centers and replacing the normal follicle mantle (mantle zone pattern).[5] At more advanced stages of tumor infiltration, MCL cells in the lymph nodes may show a vaguely nodular, or a diffuse, growth pattern.[1,6]

The classic cytologic appearance of MCL is a monomorphic proliferation of small- to medium-sized lymphoid cells with irregular nuclear contours and inconspicuous nucleoli.[1] Four cytologic variants of MCL can be recognized, including the small cell variant, the marginal zone–like variant, the blastoid variant, and the pleomorphic variant.[1,6] The blastoid and pleomorphic variants are considered to be associated with a poorer prognosis.[1]

The histologic diagnosis can be difficult, and immunophenotyping is usually required (Table 1). MCL cells express mature B-cell markers and IgM and/or IgD surface immunoglobulins (Igs). They are usually expressing CD5 but are negative for CD10 and BCL6. BCL2 protein is usually expressed, and Cyclin D1 expression, which is ectopically expressed because of the presence of the t(11;14)(q13;q32) translocation, can be shown in nearly all cases (including the very infrequent cases with aberrant CD5-negative phenotype). However, the immunohistochemistry efficiency in determining Cyclin D1 overexpression could be hampered by the quality of available material. Thus, fluorescence in situ hybridization (Figure 1) is the technique of choice to demonstrate the presence of the translocation t(11;14). Polymerase chain reaction (PCR) with primers directed to the breakpoint regions on 11q13 and 14q32 has a high false-negative rate (40%-60%); when positive, however, it is an excellent tool for molecular follow-up studies.[6] These can be useful for the evaluation of the activity of new drugs or treatment strategies, whereas in clinical practice we abandoned this analysis, being expensive, time-consuming, and not useful for clinical decisions.

Molecular pathogenesis

The genetic hallmark of MCL is the t(11;14)(q13;q32) that fuses the Ig heavy chain enhancer-promoter to the transcription unit of the proto-oncogene *CCND1*, encoding Cyclin D1.[7] The translocation determines the ectopic and deregulated expression of Cyclin D1, which is considered the primary molecular event in the pathogenesis of MCL, but additional oncogenic events are involved in MCL tumor progression. Comparative genomic hybridization and array-based genomic studies have shown a variety of altered chromosomal regions in MCL, with genomic losses containing the loci of tumor suppressor genes (including *ATM*, *CDKN2A*, *TP53*) and gains involving oncogenes (eg, *MYC*, *SYK*, *BCL2*). The presence of ataxia-telangiectasia mutated or cell-cycle checkpoint kinase 2 inactivating mutations in the germline of some MCL patients suggests that they can be implicated in development of the tumor and a model of multistep clinicopathologic and molecular pathogenesis, and progression has been proposed (Figure 2).[8]

A pronounced cell-cycle deregulation and the activation of abnormal pathways offer several possible therapeutic targets.[6,8-10]

Clinical features

In Western countries, MCL accounts for approximately 3% to 10% of all cases of non-Hodgkin lymphoma,[11,12] with a striking

Submitted February 6, 2009; accepted April 30, 2009. Prepublished online as *Blood* First Edition paper, June 25, 2009; DOI 10.1182/blood-2009-02-179739.

© 2009 by The American Society of Hematology

From www.bloodjournal.org by on August 20, 2009. For personal use only.

Table 1. Main immunohistochemical markers enabling the distinction of MCL from other lymphomas

Histologic subtype	CD5	CD23	CD43	CD10	BCL6	Cyclin D1	sIg	sIg type	cIg
MCL	+	−	+	−	−	+	+	M ± D	−
Follicular lymphoma	−	−/+	−	+/−	+	−	+	G ± M	−
Small lymphocytic lymphoma/CLL	+	+	+	−	−	−	+	M ± D	−/+
Lymphoplasmacytic lymphoma	−	−	−/+	−	−	−	+/−	M	+
Splenic marginal zone lymphoma	−	−	−	−	−	−	+	M+ D	−/+
Extranodal marginal zone lymphoma (MALT type)	−	−/+	−/+	−	−	−	+	M	+/−

MCL differential diagnosis is not always straightforward, and immunohistochemical studies are usually needed: the most typical immunophenotypic features of indolent mature B-cell neoplasms are summarized.

sIg indicates surface immunoglobulin; cIg, cytoplasmic immunoglobulin; +, > 90% positive; +/−, > 50% positive; −/+, < 50% positive; and −, < 10% positive.

predominance of the male sex (~ 2:1 or greater in all series). The patients have a median age of 60 to 65 years and typically present with generalized nonbulky lymphadenopathy. Most cases are diagnosed at advanced Ann Arbor stage, and extranodal involvement is very frequent. Most common extranodal sites include bone marrow, liver, spleen, the Waldeyer ring, and the gastrointestinal tract, this latter often with the appearance of a multiple lymphomatous polyposis of the intestine. A clearly leukemic blood picture is not uncommon, and some degree of peripheral blood involvement can be detected in nearly all cases by flow cytometry.[13] Skin involvement is usually a manifestation of disseminated disease and is often associated with blastoid cytologic features.[14] Symptomatic involvement of the central nervous system is exceedingly rare at presentation, but relapses in the central nervous system have been reported in 4% to 22% in retrospective series,[15] more frequently in patients with blastoid histology[16] and in the very rare subset of Cyclin D1–negative MCL.[17]

The clinical course is often indolent or moderately aggressive at diagnosis, with few or no symptoms and a good performance status, but with time the disease invariably become clinically aggressive and chemotherapy refractory, showing the worst long-term survival among all B-cell lymphoma subtypes[18] (Figure 3). The median survival in most published series was in the range of 3 years in the past decades and has been reported to have risen to 5 years in most recent times.[19] However, a subset of patients may show prolonged indolent behavior and a longer survival. Unfortunately, there are no reliable tools to prospectively identify these cases.

Prognostic factors

The choice of the best treatment for each individual patient and the proper evaluation of the novel therapeutic options requires the possibility of stratifying the patients according to their individual risk of relapse and death. Gene expression analysis profiles identified a cohort of 20 "proliferation signature" genes that predict patient survival,[20] but this approach cannot be applied in daily practice. A PCR-based surrogate method based on a 5-gene model and which can as well be applied on paraffin-embedded tissue has been recently proposed,[21] but it still needs proper validation. In addition to the common lymphoma indicators of prognosis (extranodal involvement, stage, age, performance status, lactic dehydrogenase), the Ki-67 proliferation index seems the most powerful predictor of survival in MCL also in the rituximab era.[5,22] A blastoid morphology has often been associated with poorer outcome,[23] whereas the influence of the growth pattern on survival is less clear.[24-26] The utility of the International Prognostic Index is controversial, but recently a specific MCL prognostic score (Mantle Cell International Prognostic Index) has been proposed.[27] This score, based on the study of 455 patients only (the International Prognostic Index and the Follicular Lymphoma International Prognostic Index as a comparison are based on series of thousands of cases), identified 4 independent prognostic factors (age, performance status, lactic dehydrogenase, and leukocyte count) that can be used to stratify patients into 3 risk groups with an overall survival (OS) of approximately 2 (high risk), 4 (intermediate) and 6 years (low risk).

Leukemic presentation and splenomegaly have been considered adverse prognostic indicators[28]; however, recent data suggest that, if associated with the lack of nodal disease (especially if showing small cell variant morphology), they may indicate a subset of patients with particularly indolent behavior.[29,30]

All the aforementioned prognostic factors correlate with survival, but none of them was validated as a tool for the selection of therapy.

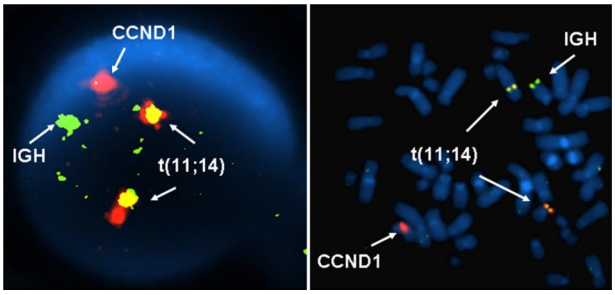

Figure 1. Fluorescence in situ hybridization analysis on interphase and metaphase nuclei (using the LSI *IGH/CCND1* XT dual-color, dual-fusion translocation DNA probe) identifying the presence of the t(11;14)(q13;q32) chromosomal translocation. Interphase nuclei are shown in the left panel. One orange (*CCND1* on chromosome 11q13), one green (IGH on chromosome 14q32), and 2 fusion signal patterns (der(11) and der(14), indicating the chromosomal rearrangements produced by the translocation) can be observed.

Staging procedures

Standard staging procedures include routine laboratory analysis, bone marrow examination as well as immunophenotyping by flow cytometry of bone marrow and peripheral blood, computed tomography scan of the chest, the abdomen and the pelvis. There is very limited information on the use of [18F]fluorodeoxyglucose positron emission tomography in MCL[31-33] hence, at present, the use of [18F]fluorodeoxyglucose positron emission tomography in MCL should still be considered investigational.

Cerebrospinal fluid evaluation is not usually required at presentation for MCL patients with classic morphology, unless neurologic symptoms are present. However, careful cerebrospinal fluid examination by cytology and flow cytometry should be considered in the initial staging of patients with the blastoid variant.[16]

From www.bloodjournal.org by on August 20, 2009. For personal use only.

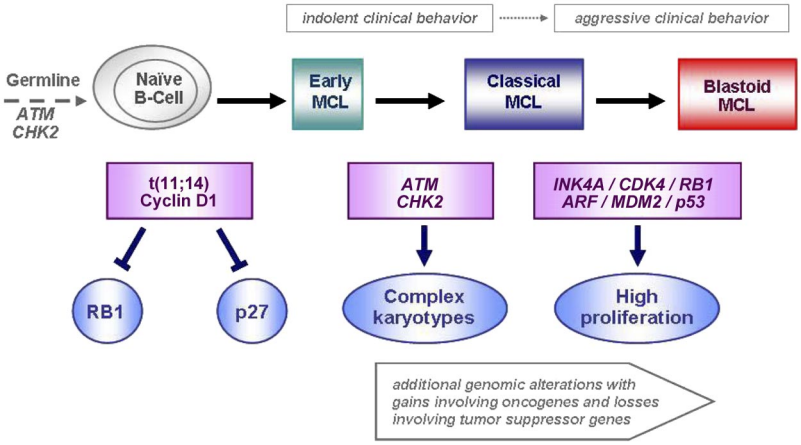

Figure 2. Model of molecular pathogenesis and progression of MCL proposed by Jares et al.[8] Ataxia-telangiectasia mutated or cell-cycle checkpoint kinase 2 inactivating mutations have been found in the germline of some MCL patients, and it has been suggested that these mutations may facilitate the lymphoma development. The t(11;14)(q13;q32) translocation occurs in an immature B cell and results in the ectopic and deregulated expression of Cyclin D1, and early expansion of tumor B cells in the mantle zone areas of lymphoid follicles. This translocation is considered a primary pathogenetic event that deregulates the cell-cycle control, probably by overcoming the suppressor effect of retinoblastoma 1 (*RB1*) and the cell-cycle inhibitor p27. Acquired inactivation of DNA damage response pathways may then facilitate additional oncogenic events and the development of classic MCL. Further genetic alterations may target genes of the cell-cycle and survival regulatory pathways, leading to more proliferative and aggressive variants. Adapted from Jares et al[8] with permission.

Gastrointestinal involvement is a common feature, which however may not necessarily be symptomatic at presentation and can therefore be easily missed if endoscopy studies are not performed. Gastrointestinal symptoms are present in approximately one-fourth of patients but, when baseline endoscopy studies are performed, gastrointestinal tract involvement can be found in up to 80% of cases, often in biopsies from macroscopically normal mucosa.[34,35] Although not an essential examination, because of the modest impact on therapeutic decisions,[34] we usually perform upper and lower endoscopy in all patients who are fit enough to tolerate it, with the purpose of better defining the indication to localized treatment in the rare patients with early stage disease and for the purpose of better documenting complete response (CR) in patients included into clinical trials.

Therapy

There are few solid data on how to treat MCL. This surprising fact is the result of the recent definition of the disease, its relatively low incidence and the lack, until very recently, of a reliable and specific prognostic score[27] that can be used in comparing data from different trials. The approach to treatment is largely based on the common belief that the disease is aggressive, although a survival of 86% at 3 years and a median overall survival of 7 years was recently described in a nonaggressively treated cohort.[36] While planning treatment for a new patient with MCL, physicians face several open questions, which are addressed in the following sections.

Best combination chemotherapy regimen

The active regimens in MCL are the same that are used for other lymphoma entities: alkylators-based (COP/CVP),[37-41] anthracycline-based (CHOP),[37-39] cladribine-[42] or fludarabine-based (FC, FCM),[43] or, more recently, bendamustine-based (BOP)[44] regimens, usually combined with rituximab.[45] The data summarizing the outcome of the chemotherapy regimens most commonly used in first line are presented in Table 2.[37-40,46-48] The majority of prospective data are available for CVP or CHOP-like regimens because fludarabine- or cladribine-based regimens[42,43] were used only for patients not considered for autologous transplantation.

However, both the randomized study and the interstudy comparisons suggest that no combination is superior in terms of OS. Therefore, the choice of the regimen depends chiefly on the overall goal, at which the treating physician and the patient are aiming. If an intensification with high-dose chemotherapy and peripheral blood stem cell transplantation (PBSCT) are planned and therefore a CR should be obtained, then an R-CHOP–like or even a more intensive regimen should be chosen. The CVAD regimen, including a continuous infusion of doxorubicin and hyperfractionated cyclophosphamide showed excellent results,[49] which were further

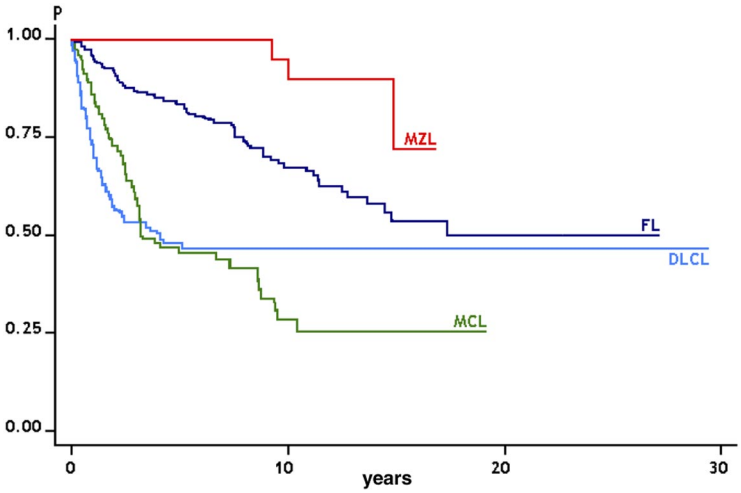

Figure 3. Cause-specific survival of the main B-cell lymphoma subtypes in the series of the Oncology Institute of Southern Switzerland, 1980-2006. MZL indicates marginal zone lymphoma; and DLCL, diffuse large cell lymphoma.

From www.bloodjournal.org by on August 20, 2009. For personal use only.

Table 2. Large (≥ 30 patients) prospective studies of combination regimens for MCL in first line

Regimen	Reference (year)	N	ORR, %	CRR, %	PFS/EFS, months	2-Year OS, %
COP/CVP	Meusers et al[37] (1989)	37	84	22	10	65
	Teodorovic et al[40] (1995)	35	60	40	20	45
	Unterhalt et al[41] (1996)	46	83	18	—	—
CHOP	Meusers et al[37] (1989)	26	88	38	7	60
	Lenz et al[38] (2005)	60	75	7	19	76
	Nickenig et al[39] (2006)	46	87	15	21	85
MCP	Nickenig et al[39] (2006)	40	73	20	15	85
	Herold et al[48] (2008)	46	63	15	13	—
R-MCP	Herold et al[48] (2008)	44	71	32	18	—
R-CHOP	Lenz et al[38] (2005)	62	94	34	20	76
	Howard et al[47] (2002)	40	96	48	17	—
VcR-CVAD	Kahl et al[46] (2008)	30	90	77	73% at 18 months	97% at 18 months

enhanced by the addition of rituximab and bortezomib, although at the expense of more frequent and severe neuropathy.[46]

Role of cytarabine (Ara-C)

As cytarabine was shown to be very active in the treatment of MCL, several investigators integrated it in first-line regimens, either as part of classic salvage combinations, such as DHAP or at high dose as used in the treatment of acute leukemia. As shown in Table 3,[50-58] the addition of cytarabine improves the rate and quality of responses as well as their duration, but at the expense of a higher toxicity: approximately 5% toxic deaths, 15% severe infections, 30% severe thrombocytopenia. This option is therefore applicable only for younger patients preparing for autologous transplantation and treated in referral centers.[50-57,59]

Transplantation: when and how

Intense chemotherapy results in a high proportion of responses and CRs, but these are usually of shorter duration than in other lymphoma types. To enhance these results and with the hope of some cures, younger patients are generally consolidated with high-dose chemotherapy and PBSCT. Data of cohorts undergoing intensive induction followed by PBSCT consolidation suggest indeed a higher event-free survival (EFS) and possibly OS compared with historical controls (Table 4),[50,59-65] but the only randomized study[60] did not as yet reach conclusive results. All data suggest that there is no disease-free plateau and therefore probably all patients will eventually relapse. An exception is represented by the recently published Nordic trial, including 160 patients[61] treated with R-maxi-CHOP alternating with HD-Ara-C and consolidation with BEAM or BEAC supported by in vivo R-purged autologous stem cells. In this study with a median observation of 4 years, a 6-year EFS of 56% was observed with no patient relapsing after 5 years. Similar data are seen for 63 patients transplanted in CR and included in bone marrow transplantation registries.[66]

As in other indolent lymphomas, allogeneic bone marrow transplantation is the only potentially curative treatment for advanced disease, but its application is limited by the important age-dependent mortality. Even with nonmyeloablative conditioning, the transplantation-related mortality in registry data were 50% and the OS 30% at 2 years,[67] although some centers of excellence present more encouraging data.[68-70] The evidence of a graft-versus-lymphoma effect in MCL is weaker than for follicular lymphoma (FL)[67,71] and registry data of transplanted MCL do not clearly show a plateau suggesting cure, although a few relapsed patients experienced very long remissions.

Rituximab in MCL

In MCL, rituximab has a somehow less impressive activity than in other B-cell indolent malignancies. The response rate in both untreated and pretreated patients is approximately 30% and the median duration of response 6 months.[72,73] When combined with chemotherapy, it improves the CR rate[47-49,52] and a comprehensive systematic review and meta-analysis of 7 randomized controlled trials indicated that rituximab plus chemotherapy may be superior to chemotherapy alone with respect to OS in MCL (hazard ratio for mortality = 0.60; 95% confidence interval, 0.37-0.98). In this meta-analysis, however, there was a strong heterogeneity among the trials, making this survival benefit not completely reliable.[74] Used as maintenance after either single-agent rituximab, chemotherapy, or chemo-immunotherapy induction, rituximab marginally improves EFS but has no effect on OS.[73,75]

Table 3. Large prospective studies of cytarabine intensification for first-line MCL

Regimen	Reference (year)	N	ORR, %	CRR, %	Toxicity grade III-IV
Hyper-CVAD/MTX-Ara-C	Khouri et al[50] (1998)	45 (20 untreated)	93	38	Thrombocytopenia 85%, infections 10%
Hyper-CVAD/MTX-Ara-C	Romaguera et al[58] (2000)	25 (age > 65 y)	92	68	Toxic death 8%, infections 5%
R-Hyper-CVAD/R-MTX-Ara-C	Romaguera et al[52] (2005)	97	97	87	Toxic death 5%, MDS 3%
R-Hyper-CVAD/R-MTX-Ara-C	Epner et al[53] (2007)	49	88	58	Toxic death 2%, hematotoxicity 87%
R-Hyper-CVAD/R-MTX-Ara-C	Merli et al[54] (2008)	32	53	50	Toxic death 6%, severe infections 15%
R-DHAP	de Guibert et al[57] (2006)	25	96	92	Thrombocytopenia 33%
CHOP × 3 + DHAP × 3	Lefrère et al[51] (2004)	28	92	84	—
R-CHOP × 3 + R-DHAP × 3	Delarue et al[55] (2008)	60	95	61	—
R-CHOP × 3 + HD-Ara-C × 1	van't Veer et al[56] (2008)	87	72	29	Infections 30%

From www.bloodjournal.org by on August 20, 2009. For personal use only.

Table 4. Main prospective studies of PBSCT consolidation in first-line MCL

Regimen	Reference (year)	N	3-year EFS, %	3-year OS, %	Main toxicity
Hyper-CVAD/HD-MTX-Ara-C	Khouri et al[50] (1998)	25	72	92	—
	Khouri et al[59] (2003)	31	43% at 5 years	77% at 5 years	—
3 × APO + rituximab + sequential high-dose	Gianni et al[62] (2003)	28	80	90	18% CMV reactivation
CHOP + HD-CVB + rituximab	Mangel et al[63] (2004)	20	89	88	Interstitial pneumonitis
6xCHOP + HDdexaBEAM	Dreyling et al[60] (2005)	62	54	83	5% toxic deaths
CTAP/VMAC + HD-BuCy	Evens et al[64] (2007)	25	50	60	
CHOP+HD-Ara-C +HD-R-Cy-TBI	Dreger et al[65] (2007)	34	80	100	79% severe mucositis
R-maxi-CHOP +R-HD-Ara-C+R-BEAM	Geisler et al[61] (2008)	160	70	85	5% toxic deaths

CMV indicates cytomegalovirus.

Role of radiotherapy

As MCL usually presents at an advanced stage, systemic treatment is the standard, and not much data are available on the activity of radiotherapy. Two retrospective studies suggest that radiotherapy is active in MCL, both alone or added to chemotherapy.[76,77] The belief of European cooperative groups that total body irradiation regimens are more appropriate than chemotherapy as conditioning regimens before PBSCT in MCL is based on weak evidence[78] and has been questioned more recently.

The recently available radioimmunotherapy (RIT) is an elegant technique to deliver radiotherapy in a targeted fashion. Anti-CD20 antibodies combined with a radioactive isotope (yttrium-90 or iodine-111) have activity in several lymphomas, including MCL. When RIT was used to consolidate remissions after (immuno)chemotherapy, it resulted in improvement of percentage, quality, and duration of responses compared with historical controls.[79] RIT was also used (at either standard or high-dose) to improve on the activity of high-dose chemotherapy in the setting of autologous stem cell transplantation, showing feasibility and suggesting a possible benefit.[80,81]

New drugs active in MCL

Several new drugs have shown a remarkable single-agent activity in relapsed or resistant MCL and many, mainly of the so-called "molecular targeted" type, are now under investigation. Of those clinically available, the more consistent response rates are 33% for bortezomib,[82] 41% to 53% for lenalidomide,[83,84] and 22% to 41% for temsirolimus.[85-87] These compounds and others are now investigated in clinical trials for their possible role in combination with other agents active in MCL. The combination of thalidomide with rituximab[88] showed remarkable activity in a small group of 16 elderly patients with relapsed disease (response rate = 81%) and the combination of bendamustine with rituximab obtained astonishingly high response rates and CR rates (75%-92% and 42%-50%, respectively).[45,89]

Suggested treatment algorithm

MCL is generally a systemic disease, but a small proportion of cases (10%-20%) is diagnosed with only one to 3 adjacent involved lymph node sites. In these cases, in analogy with the common practice for other lymphoma types, we treat these patients with involved field radiotherapy, preceded by 3 or 4 cycles of chemotherapy for patients who are young and fit enough for it. This strategy obtained long-term remissions in 11 of 16 patients treated in British Columbia.[76]

For advanced disease, considering the biologic characteristics and the treatment options illustrated in "Therapy," the issue is whether MCL should be approached as done in diffuse large B-cell lymphoma (with which it shares the aggressive biology), that is, R-CHOP–like treatment to everybody, or rather with an approach as in FL (with which it shares the characteristic of noncurability), that is, tailored treatment based on prognostic factors and clinical characteristics of the patient.

Even though immediate combination chemotherapy for those who can tolerate it has been the far most used approach in the last decades, a watch-and-wait policy could be advocated, as we know that a fraction of patients present with a rather indolent form of MCL. Investigators at the Weill Cornell Medical College recently reported on 31 asymptomatic MCL patients with median age 58 years, who were approached by observation and treated only when clinically needed (all intervals > 3 months). Fourteen of these remained without treatment for more than 1 year, and the OS of this group was similar to an institutional comparison group (n = 66) that was treated immediately at diagnosis.[90] This is an interesting observation; however, it must be noted that it comes from a retrospective analysis of a small group of cases, and to extrapolate that a watch-and-wait policy could be advocated for a selected subgroup of MCL patients may be premature.

Therefore, because MCL is to be considered a generally aggressive disease and because none of the biologic and clinical prognostic factors has been validated as a tool for the selection of therapy, our practice is to start therapy at diagnosis while tailoring treatment to the age and the general condition of the patient.

First-line treatment

Treatment of the young and fit

In several B-cell lymphomas, such as FL or diffuse large B-cell lymphoma, the advent of rituximab improved patient prognosis and changed the treatment approach, reducing the role of more aggressive treatment in front line. In MCL, in contrast, the outlook of patients has not changed significantly, and we are still facing an aggressive disease with a generally dismal prognosis, a median survival of 5 years, and a tendency to relapse early and to respond insufficiently to salvage treatment. The disease often involves the bone marrow, so that if autologous transplantation is planned, the collection of blood stem cells with the minimal amount of contaminating tumor should be performed as early as possible. For these reasons, we apply an aggressive approach for patients who are young (< 60-65 years) and fit (no relevant comorbidity). In these cases, the clinical presentation of the disease (whether

From www.bloodjournal.org by on August 20, 2009. For personal use only.

involving mainly the lymph nodes, the bone marrow, and spleen or the gut) is not relevant for the choice of therapy. In our institution, we decided to use the R-hyper-CVAD/R-HD-MTX-Ara-C regimen for 4 to 6 cycles, followed by a consolidation with BEAM and PBSCT. Even though this approach was not confirmed as optimal in randomized trials, it appears to be very active and safe enough if applied in tertiary centers with sufficient expertise in high-dose therapy. Because the incidence of MCL patients with age younger than 65 years is similar to that of AML cases of the same age, we think that the suggestion to treat them all in tertiary centers with expertise in the treatment of acute leukemia should not be considered exaggerated.

Approach to the elderly and fit

Patients too old for autologous transplantation, but who are fit enough to receive intensive treatment, should be given chemotherapy with rituximab. We have chosen to treat these cases with R-CHOP or R-CVP (depending on the cardiac comorbidities), but regimens such as R-BOP or R-FCM have as well shown to be suitable for this purpose and should be selected based on their side effect profile and the physician confidence with the regimen. Because of its toxicity profile, we do not add HD-Ara-C to these patients. On the other hand, it could be an option to consolidate these remissions with radioimmunotherapy, as it significantly improves the duration of remission without hampering the quality of life. Because of problems in obtaining payment of this expensive treatment by insurances, we are not routinely applying this option to our patients.

Treatment of the unfit

Patients who, either because of age or of comorbidities, are unable to tolerate aggressive treatment, are treated with palliative chemotherapy of reduced intensity, usually with single agents. Of all the possible options, because of the favorable toxicity and cost profile, we often still choose to give oral chlorambucil, eventually combined with rituximab. The response rate and duration of this combination are satisfactory, as is the minimal impact on the quality of life.[91]

Second-line treatments

It has been proposed that the improvement in survival observed in the last decade is not the result of better first-line treatments but rather to improved second-, third-, and fourth-line therapeutic options.[92] Whether this is true or not, when patients relapse after an aggressive approach, the goal of treatment becomes palliation of symptoms, and second-line treatments with few side effects should be preferred. An exception is the relatively rare case of young and motivated patients with a compatible donor: here we consider the possibility of an allogeneic transplantation and the pros and cons of such a procedure are discussed. If an allogeneic transplantation is foreseen, we induce remission with a cisplatin-based regimen (etoposide, Solu-Medrol, high-dose Ara-C, Platinol-ESHAP) as done for other lymphomas.

A variety of treatments have shown a good therapeutic index at relapse. They are composed of single agents as thalidomide,[88] chlorambucil,[91] bendamustine,[45,89] and cladribine,[42] or newer agents such as bortezomib,[82] lenalidomide,[93] or temsirolimus.[85] Combination treatments, such as R-FC,[94] R-FCM,[75] and gemcitabine/dexamethasone plus or minus cisplatin,[95] obtain a higher response rate but have probably no impact on survival and are at risk of causing major side effects. Low-dose metronomic PEP-C[96] is a new combination of orally administered drugs, which is both well tolerated and active.

Despite the clinical activity of many compounds and regimens, the treatment outcome of relapsing MCL patients who are not suitable for allogeneic transplantation remains dismal, and no curative options are available. Therefore, we think that, whenever possible, these patients should be offered the possibility of entering clinical trials testing new agents. When this is not possible, for practical reasons, we usually try chlorambucil first, or CVP if a rapid response is needed for symptom palliation. Bortezomib is our next choice, followed by lenalidomide, each of these eventually combined with rituximab.

Even though in some countries it is customary to add rituximab to any line of therapy for any B-cell neoplasia, we consider MCL as one of the lymphomas less sensitive to this antibody. We therefore do not add rituximab to subsequent treatments if progression occurred within 6 months from the termination of a previous R-containing therapy.

Finally, radiotherapy, either in the form of irradiation of symptomatic localizations or in the form of radio-immunotherapy, can be a good choice in selected patients. A problem with this latter form of treatment is that a bone marrow infiltration less than 25% and a normal platelet count are needed, both conditions that are not often met in relapsed MCL.

Acknowledgments

We thank our colleagues Franco Cavalli and Francesco Bertoni for critically reading the manuscript and for their fruitful feedback and thoughtful discussion, and Dr Monica Taborelli for kindly providing the photographs included in Figure 1.

Authorship

Contribution: M.G. and E.Z. wrote the paper.

Conflict-of-interest disclosure: The authors declare no competing financial interests.

Correspondence: Michele Ghielmini, Medical Oncology Departement, Oncology Institute of Southern Switzerland, Ospedale San Giovanni 6500 Bellinzona, Switzerland; e-mail: michele.ghielmini@eoc.ch.

References

1. Swerdlow SH, Campo E, Seto M, Muller-Hermelink HK. Mantle cell lymphoma. In: Swerdlow S, Campo E, Harris NL, et al, eds. *WHO Classification of Tumours of Haematopoietic and Lymphoid Tissues.* Lyon, France: IARC; 2008:229-232.
2. Lennert K. *Histopathology of Non-Hodgkin's Lymphomas: Based on the Kiel Classification.* Berlin, Germany: Springer-Verlag; 1981.
3. Banks PM, Chan J, Cleary ML, et al. Mantle cell lymphoma: a proposal for unification of morphologic, immunologic, and molecular data. *Am J Surg Pathol.* 1992;16:637-640.
4. Zucca E, Stein H, Coiffier B. European Lymphoma Task Force (ELTF): report of the workshop on Mantle Cell Lymphoma (MCL). *Ann Oncol.* 1994;5:507-511.
5. Tiemann M, Schrader C, Klapper W, et al. Histopathology, cell proliferation indices and clinical outcome in 304 patients with mantle cell lymphoma (MCL): a clinicopathological study from the European MCL Network. *Br J Haematol.* 2005;131:29-38.
6. Bertoni F, Ponzoni M. The cellular origin of mantle cell lymphoma. *Int J Biochem Cell Biol.* 2007;39:1747-1753.
7. Bertoni F, Rinaldi A, Zucca E, Cavalli F. Update

From www.bloodjournal.org by on August 20, 2009. For personal use only.

on the molecular biology of mantle cell lymphoma. *Hematol Oncol.* 2006;24:22-27.

8. Jares P, Colomer D, Campo E. Genetic and molecular pathogenesis of mantle cell lymphoma: perspectives for new targeted therapeutics. *Nat Rev Cancer.* 2007;7:750-762.
9. O'Connor OA. Mantle cell lymphoma: identifying novel molecular targets in growth and survival pathways. *Hematology Am Soc Hematol Educ Program.* 2007;2007:270-276.
10. Jares P, Campo E. Advances in the understanding of mantle cell lymphoma. *Br J Haematol.* 2008;142:149-165.
11. Anderson JR, Armitage JO, Weisenburger DD. Epidemiology of the non-Hodgkin's lymphomas: distributions of the major subtypes differ by geographic locations. Non-Hodgkin's Lymphoma Classification Project. *Ann Oncol.* 1998;9:717-720.
12. Zhou Y, Wang H, Fang W, et al. Incidence trends of mantle cell lymphoma in the United States between 1992 and 2004. *Cancer.* 2008;113:791-798.
13. Ferrer A, Salaverria I, Bosch F, et al. Leukemic involvement is a common feature in mantle cell lymphoma. *Cancer.* 2007;109:2473-2480.
14. Sen F, Medeiros LJ, Lu D, et al. Mantle cell lymphoma involving skin: cutaneous lesions may be the first manifestation of disease and tumors often have blastoid cytologic features. *Am J Surg Pathol.* 2002;26:1312-1318.
15. Gill S, Seymour JF. What is the real risk of central nervous system involvement in mantle cell lymphoma? *Leuk Lymphoma.* 2008;49:2237-2239.
16. Ferrer A, Bosch F, Villamor N, et al. Central nervous system involvement in mantle cell lymphoma. *Ann Oncol.* 2008;19:135-141.
17. Dierickx D, Wlodarska I, Vanhentenrijk V, et al. Secondary central nervous system involvement in cyclin D1-negative mantle cell lymphoma. *Leuk Lymphoma.* 2008;49:2365-2366.
18. Zucca E, Roggero E, Pinotti G, et al. Patterns of survival in mantle cell lymphoma. *Ann Oncol.* 1995;6:257-262.
19. Herrmann A, Hoster E, Zwingers T, et al. Improvement of overall survival in advanced stage mantle cell lymphoma. *J Clin Oncol.* 2009;27:511-518.
20. Rosenwald A, Wright G, Wiestner A, et al. The proliferation gene expression signature is a quantitative integrator of oncogenic events that predicts survival in mantle cell lymphoma. *Cancer Cell.* 2003;3:185-197.
21. Hartmann E, Fernandez V, Moreno V, et al. Five-gene model to predict survival in mantle-cell lymphoma using frozen or formalin-fixed, paraffin-embedded tissue. *J Clin Oncol.* 2008;26:4966-4972.
22. Determann O, Hoster E, Ott G, et al. Ki-67 predicts outcome in advanced-stage mantle cell lymphoma patients treated with anti-CD20 immunochemotherapy: results from randomized trials of the European MCL Network and the German Low Grade Lymphoma Study Group. *Blood.* 2008;111:2385-2387.
23. Bernard M, Gressin R, Lefrere F, et al. Blastic variant of mantle cell lymphoma: a rare but highly aggressive subtype. *Leukemia.* 2001;15:1785-1791.
24. Norton AJ, Matthews J, Pappa V, et al. Mantle cell lymphoma: natural history defined in a serially biopsied population over a 20-year period. *Ann Oncol.* 1995;6:249-256.
25. Majlis A, Pugh WC, Rodriguez MA, Benedict WF, Cabanillas F. Mantle cell lymphoma: correlation of clinical outcome and biologic features with three histologic variants. *J Clin Oncol.* 1997;15:1664-1671.
26. Weisenburger DD, Vose JM, Greiner TC, et al. Mantle cell lymphoma: a clinicopathologic study of 68 cases from the Nebraska Lymphoma Study Group. *Am J Hematol.* 2000;64:190-196.
27. Hoster E, Dreyling M, Klapper W, et al. A new prognostic index (MIPI) for patients with advanced-stage mantle cell lymphoma. *Blood.* 2008;111:558-565.
28. Molina TJ, Delmer A, Cymbalista F, et al. Mantle cell lymphoma, in leukaemic phase with prominent splenomegaly: a report of eight cases with similar clinical presentation and aggressive outcome. *Virchows Arch.* 2000;437:591-598.
29. Nodit L, Bahler DW, Jacobs SA, Locker J, Swerdlow SH. Indolent mantle cell lymphoma with nodal involvement and mutated immunoglobulin heavy chain genes. *Hum Pathol.* 2003;34:1030-1034.
30. Orchard J, Garand R, Davis Z, et al. A subset of t(11;14) lymphoma with mantle cell features displays mutated IgVH genes and includes patients with good prognosis, nonnodal disease. *Blood.* 2003;101:4975-4981.
31. Tsukamoto N, Kojima M, Hasegawa M, et al. The usefulness of (18)F-fluorodeoxyglucose positron emission tomography ((18)F-FDG-PET) and a comparison of (18)F-FDG-pet with (67)gallium scintigraphy in the evaluation of lymphoma: relation to histologic subtypes based on the World Health Organization classification. *Cancer.* 2007;110:652-659.
32. Gill S, Wolf M, Prince HM, et al. [18F]fluorodeoxyglucose positron emission tomography scanning for staging, response assessment, and disease surveillance in patients with mantle cell lymphoma. *Clin Lymphoma Myeloma.* 2008;8:159-165.
33. Brepoels L, Stroobants S, De Wever W, et al. Positron emission tomography in mantle cell lymphoma. *Leuk Lymphoma.* 2008;49:1693-1701.
34. Romaguera JE, Medeiros LJ, Hagemeister FB, et al. Frequency of gastrointestinal involvement and its clinical significance in mantle cell lymphoma. *Cancer.* 2003;97:586-591.
35. Salar A, Juanpere N, Bellosillo B, et al. Gastrointestinal involvement in mantle cell lymphoma: a prospective clinic, endoscopic, and pathologic study. *Am J Surg Pathol.* 2006;30:1274-1280.
36. Martin P, Chadburn A, Christos P, et al. Intensive treatment strategies may not provide superior outcomes in mantle cell lymphoma: overall survival exceeding 7 years with standard therapies. *Ann Oncol.* 2008;19:1327-1330.
37. Meusers P, Engelhard M, Bartels H, et al. Multicentre randomized therapeutic trial for advanced centrocytic lymphoma: anthracycline does not improve the prognosis. *Hematol Oncol.* 1989;7:365-380.
38. Lenz G, Dreyling M, Hoster E, et al. Immunochemotherapy with rituximab and cyclophosphamide, doxorubicin, vincristine, and prednisone significantly improves response and time to treatment failure, but not long-term outcome in patients with previously untreated mantle cell lymphoma: results of a prospective randomized trial of the German Low Grade Lymphoma Study Group (GLSG). *J Clin Oncol.* 2005;23:1984-1992.
39. Nickenig C, Dreyling M, Hoster E, et al. Combined cyclophosphamide, vincristine, doxorubicin, and prednisone (CHOP) improves response rates but not survival and has lower hematologic toxicity compared with combined mitoxantrone, chlorambucil, and prednisone (MCP) in follicular and mantle cell lymphomas: results of a prospective randomized trial of the German Low-Grade Lymphoma Study Group. *Cancer.* 2006;107:1014-1022.
40. Teodorovic I, Pittaluga S, Kluin-Nelemans JC, et al. Efficacy of four different regimens in 64 mantle-cell lymphoma cases: clinicopathologic comparison with 498 other non-Hodgkin's lymphoma subtypes. European Organization for the Research and Treatment of Cancer Lymphoma Cooperative Group. *J Clin Oncol.* 1995;13:2819-2826.
41. Unterhalt M, Herrmann R, Tiemann M, et al. Prednimustine, mitoxantrone (PmM) vs cyclophosphamide, vincristine, prednisone (COP) for the treatment of advanced low-grade non-Hodgkin's lymphoma: German Low-Grade Lymphoma Study Group. *Leukemia.* 1996;10:836-843.
42. Inwards DJ, Fishkin PA, Hillman DW, et al. Long-term results of the treatment of patients with mantle cell lymphoma with cladribine (2-CDA) alone (95-80-53) or 2-CDA and rituximab (N0189) in the North Central Cancer Treatment Group. *Cancer.* 2008;113:108-116.
43. Cohen BJ, Moskowitz C, Straus D, Noy A, Hedrick E, Zelenetz A. Cyclophosphamide/fludarabine (CF) is active in the treatment of mantle cell lymphoma. *Leuk Lymphoma.* 2001;42:1015-1022.
44. Herold M, Schulze A, Niederwieser D, et al. Bendamustine, vincristine and prednisone (BOP) versus cyclophosphamide, vincristine and prednisone (COP) in advanced indolent non-Hodgkin's lymphoma and mantle cell lymphoma: results of a randomised phase III trial (OSHO# 19). *J Cancer Res Clin Oncol.* 2006;132:105-112.
45. Rummel MJ, Al-Batran SE, Kim SZ, et al. Bendamustine plus rituximab is effective and has a favorable toxicity profile in the treatment of mantle cell and low-grade non-Hodgkin's lymphoma. *J Clin Oncol.* 2005;23:3383-3389.
46. Kahl B, Chang J, Eickhoff J, et al. VcR-CVAD produces a high complete response rate in untreated mantle cell lymphoma: a phase II study from the Wisconsin Oncology Network. *Blood.* 2008;112:104-105. Abstract 265.
47. Howard OM, Gribben JG, Neuberg DS, et al. Rituximab and CHOP induction therapy for newly diagnosed mantle-cell lymphoma: molecular complete responses are not predictive of progression-free survival. *J Clin Oncol.* 2002;20:1288-1294.
48. Herold M, Haas A, Doerken B, et al. Immunochemotherapy (R-MCP) in advanced mantle cell lymphoma is not superior to chemotherapy (MCP) alone: 50 months up date of the OSHO phase III study (OSHO#39). *Ann Oncol.* 2008;19:iv86. Abstract O12.
49. Kahl BS, Longo WL, Eickhoff JC, et al. Maintenance rituximab following induction chemoimmunotherapy may prolong progression-free survival in mantle cell lymphoma: a pilot study from the Wisconsin Oncology Network. *Ann Oncol.* 2006;17:1418-1423.
50. Khouri IF, Romaguera J, Kantarjian H, et al. Hyper-CVAD and high-dose methotrexate/cytarabine followed by stem-cell transplantation: an active regimen for aggressive mantle-cell lymphoma. *J Clin Oncol.* 1998;16:3803-3809.
51. Lefrère F, Delmer A, Levy V, Delarue R, Varet B, Hermine O. Sequential chemotherapy regimens followed by high-dose therapy with stem cell transplantation in mantle cell lymphoma: an update of a prospective study. *Haematologica.* 2004;89:1275-1276.
52. Romaguera JE, Fayad L, Rodriguez MA, et al. High rate of durable remissions after treatment of newly diagnosed aggressive mantle-cell lymphoma with rituximab plus hyper-CVAD alternating with rituximab plus high-dose methotrexate and cytarabine. *J Clin Oncol.* 2005;23:7013-7023.
53. Epner EM, Unger J, Miller T, et al. A multicenter trial of hyper-CVAD + rituxan in patients with newly diagnosed mantle cell lymphoma. *Blood.* 2007;110:121a. Abstract 387.
54. Merli F, Luminari S, Ilariucci F, et al. Rituximab plus Hypercvad alternating with high dose methotrexate and cytarabine for patients with newly diagnosed mantle cell lymphoma: a multicenter trial

From www.bloodjournal.org by on August 20, 2009. For personal use only.

from GISL. *Blood.* 2008;112:1048-1049. Abstract 3050.

55. Delarue R, Haioun C, Ribrag V, et al. RCHOP and RDHAP followed by autologous stem cell transplantation (ASCT) in mantle cell lymphoma (MCL): final results of a phase II study from the GELA. *Blood.* 2008;112:218. Abstract 581.
56. van't Veer MB, de Jong D, Mackenzie M, et al. High-dose Ara-C and beam with autograft rescue in R-CHOP responsive mantle cell lymphoma patients. *Br J Haematol.* 2009;144:524-530.
57. de Guibert S, Jaccard A, Bernard M, Turlure P, Bordessoule D, Lamy T. Rituximab and DHAP followed by intensive therapy with autologous stem-cell transplantation as first-line therapy for mantle cell lymphoma. *Haematologica.* 2006;91:425-426.
58. Romaguera JE, Khouri IF, Kantarjian HM, et al. Untreated aggressive mantle cell lymphoma: results with intensive chemotherapy without stem cell transplant in elderly patients. *Leuk Lymphoma.* 2000;39:77-85.
59. Khouri IF, Saliba RM, Okoroji GJ, Acholonu SA, Champlin RE. Long-term follow-up of autologous stem cell transplantation in patients with diffuse mantle cell lymphoma in first disease remission: the prognostic value of beta2-microglobulin and the tumor score. *Cancer.* 2003;98:2630-2635.
60. Dreyling M, Lenz G, Hoster E, et al. Early consolidation by myeloablative radiochemotherapy followed by autologous stem cell transplantation in first remission significantly prolongs progression-free survival in mantle-cell lymphoma: results of a prospective randomized trial of the European MCL Network. *Blood.* 2005;105:2677-2684.
61. Geisler CH, Kolstad A, Laurell A, et al. Long-term progression-free survival of mantle cell lymphoma after intensive front-line immunochemotherapy with in vivo-purged stem cell rescue: a nonrandomized phase 2 multicenter study by the Nordic Lymphoma Group. *Blood.* 2008;112:2687-2693.
62. Gianni AM, Magni M, Martelli M, et al. Long-term remission in mantle-cell lymphoma following high-dose sequential chemotherapy and in vivo rituximab-purged stem cell autografting (R-HDS regimen). *Blood.* 2003;102:749-755.
63. Mangel J, Leitch HA, Connors JM, et al. Intensive chemotherapy and autologous stem-cell transplantation plus rituximab is superior to conventional chemotherapy for newly diagnosed advanced stage mantle-cell lymphoma: a matched pair analysis. *Ann Oncol.* 2004;15:283-290.
64. Evens AM, Winter JN, Hou N, et al. A phase II clinical trial of intensive chemotherapy followed by consolidative stem cell transplant: long-term follow-up in newly diagnosed mantle cell lymphoma. *Br J Haematol.* 2008;140:385-393.
65. Dreger P, Rieger M, Seyfarth B, et al. Rituximab-augmented myeloablation for first-line autologous stem cell transplantation for mantle cell lymphoma: effects on molecular response and clinical outcome. *Haematologica.* 2007;92:42-49.
66. Vandenberghe E, Ruiz de Elvira C, Loberiza FR, et al. Outcome of autologous transplantation for mantle cell lymphoma: a study by the European Blood and Bone Marrow Transplant and Autologous Blood and Marrow Transplant Registries. *Br J Haematol.* 2003;120:793-800.
67. Kiss TL, Mollee P, Lazarus HM, Lipton JH. Stem cell transplantation for mantle cell lymphoma: if, when and how? *Bone Marrow Transplant.* 2005;36:655-661.
68. Maris MB, Sandmaier BM, Storer BE, et al. Allogeneic hematopoietic cell transplantation after fludarabine and 2 Gy total body irradiation for relapsed and refractory mantle cell lymphoma. *Blood.* 2004;104:3535-3542.
69. Khouri IF, Lee MS, Saliba RM, et al. Nonablative allogeneic stem-cell transplantation for advanced/recurrent mantle-cell lymphoma. *J Clin Oncol.* 2003;21:4407-4412.
70. Khouri F, Tam CS, Ledesma C, Champlin RE. Non-myeloablative allogeneic stem cell transplantation (NST) vs. autologous transplantation (ASCT) in patients with mantle cell lymphoma (MCL). *Ann Oncol.* 2008;19:iv86. Abstract O14.
71. Corradini P, Dodero A, Farina L, et al. Allogeneic stem cell transplantation following reduced-intensity conditioning can induce durable clinical and molecular remissions in relapsed lymphomas: pre-transplant disease status and histotype heavily influence outcome. *Leukemia.* 2007;21:2316-2323.
72. Foran JM, Cunningham D, Coiffier B, et al. Treatment of mantle-cell lymphoma with rituximab (chimeric monoclonal anti-CD20 antibody): analysis of factors associated with response. *Ann Oncol.* 2000;11:117-121.
73. Ghielmini M, Schmitz SF, Cogliatti S, et al. Effect of single-agent rituximab given at the standard schedule or as prolonged treatment in patients with mantle cell lymphoma: a study of the Swiss Group for Clinical Cancer Research (SAKK). *J Clin Oncol.* 2005;23:705-711.
74. Schulz H, Bohlius JF, Trelle S, et al. Immunochemotherapy with rituximab and overall survival in patients with indolent or mantle cell lymphoma: a systematic review and meta-analysis. *J Natl Cancer Inst.* 2007;99:706-714.
75. Forstpointner R, Unterhalt M, Dreyling M, et al. Maintenance therapy with rituximab leads to a significant prolongation of response duration after salvage therapy with a combination of rituximab, fludarabine, cyclophosphamide, and mitoxantrone (R-FCM) in patients with recurring and refractory follicular and mantle cell lymphomas: results of a prospective randomized study of the German Low Grade Lymphoma Study Group (GLSG). *Blood.* 2006;108:4003-4008.
76. Leitch HA, Gascoyne RD, Chhanabhai M, Voss NJ, Klasa R, Connors JM. Limited-stage mantle-cell lymphoma. *Ann Oncol.* 2003;14:1555-1561.
77. Rosenbluth BD, Yahalom J. Highly effective local control and palliation of mantle cell lymphoma with involved-field radiation therapy (IFRT). *Int J Radiat Oncol Biol Phys.* 2006;65:1185-1191.
78. Milpied N, Gaillard F, Moreau P, et al. High-dose therapy with stem cell transplantation for mantle cell lymphoma: results and prognostic factors, a single center experience. *Bone Marrow Transplant.* 1998;22:645-650.
79. Smith MR, Lijun Zhang L, Gordon LI, et al. Phase II Study of R-CHOP followed by 90Y-ibritumomab tiuxetan in untreated mantle cell lymphoma: Eastern Cooperative Oncology Group Study E1499. *Blood.* 2007;110:389.
80. Gopal AK, Rajendran JG, Petersdorf SH, et al. High-dose chemo-radioimmunotherapy with autologous stem cell support for relapsed mantle cell lymphoma. *Blood.* 2002;99:3158-3162.
81. Krishnan A, Nademanee A, Fung HC, et al. Phase II trial of a transplantation regimen of yttrium-90 ibritumomab tiuxetan and high-dose chemotherapy in patients with non-Hodgkin's lymphoma. *J Clin Oncol.* 2008;26:90-95.
82. Fisher RI, Bernstein SH, Kahl BS, et al. Multicenter phase II study of bortezomib in patients with relapsed or refractory mantle cell lymphoma. *J Clin Oncol.* 2006;24:4867-4874.
83. Zinzani PL, Witzig TE, Vose JM, et al. Confirmation of the efficacy and safety of lenalidomide oral monotherapy in patients with relapsed or refractory mantle-cell lymphoma: results of an international study (NHL-003). *Blood.* 2008;112:262.
84. Habermann TM, Lossos IS, Justice G, et al. Lenalidomide oral monotherapy produces a high response rate in patients with relapsed or refractory mantle cell lymphoma. *Br J Haematol.* 2009;145:344-349.
85. Witzig TE, Geyer SM, Ghobrial I, et al. Phase II trial of single-agent temsirolimus (CCI-779) for relapsed mantle cell lymphoma. *J Clin Oncol.* 2005;23:5347-5356.
86. Ansell SM, Inwards DJ, Rowland KM Jr, et al. Low-dose, single-agent temsirolimus for relapsed mantle cell lymphoma: a phase 2 trial in the North Central Cancer Treatment Group. *Cancer.* 2008;113:508-514.
87. Hess G, Romaguera JE, Verhoef G, et al. Phase III study of patients with relapsed, refractory mantle cell lymphoma treated with temsirolimus compared with investigator's choice therapy. *J Clin Oncol.* 2008;26:8513.
88. Kaufmann H, Raderer M, Woehrer S, et al. Antitumor activity of rituximab plus thalidomide in patients with relapsed/refractory mantle cell lymphoma. *Blood.* 2004;104:2269-2271.
89. Robinson KS, Williams ME, van der Jagt RH, et al. Phase II multicenter study of bendamustine plus rituximab in patients with relapsed indolent B-cell and mantle cell non-Hodgkin's lymphoma. *J Clin Oncol.* 2008;26:4473-4479.
90. Martin P, Chadburn A, Christos P, et al. Outcome of deferred initial therapy in mantle-cell lymphoma. *J Clin Oncol.* 2009;27:1209-1213.
91. Bauwens D, Maerevoet M, Michaux L, et al. Activity and safety of combined rituximab with chlorambucil in patients with mantle cell lymphoma. *Br J Haematol.* 2005;131:338-340.
92. Martin P, Coleman M, Leonard JP. Progress in mantle-cell lymphoma. *J Clin Oncol.* 2009;27:481-483.
93. Wiernik PH, Lossos IS, Tuscano JM, et al. Lenalidomide monotherapy in relapsed or refractory aggressive non-Hodgkin's lymphoma. *J Clin Oncol.* 2008;26:4952-4957.
94. Thomas DW, Owen RG, Johnson SA, et al. Superior quality and duration of responses among patients with mantle-cell lymphoma treated with fludarabine and cyclophosphamide with or without rituximab compared with prior responses to CHOP. *Leuk Lymphoma.* 2005;46:549-552.
95. Morschhauser F, Depil S, Jourdan E, et al. Phase II study of gemcitabine-dexamethasone with or without cisplatin in relapsed or refractory mantle cell lymphoma. *Ann Oncol.* 2007;18:370-375.
96. Coleman M, Martin P, Ruan J, et al. Low-dose metronomic, multidrug therapy with the PEP-C oral combination chemotherapy regimen for mantle cell lymphoma. *Leuk Lymphoma.* 2008;49:447-450.